

# Topical wound oxygen therapy for chronic diabetic lower limb ulcers and sacral pressure ulcers in Japan



**Authors:**  
Hitomi Sano, Shigeru Ichioka

Topical wound oxygen therapy (TWO) is widely used in North America and Europe. We initiated a clinical trial in 2010 to introduce this therapy into Japan; this involved six patients with chronic ulcers who underwent TWO. Pre- and post-treatment transcutaneous oxygen tension (TcPO<sub>2</sub>) values were evaluated at the periwound area. All cases showed increased TcPO<sub>2</sub> values after TWO. In four cases, the size of the wound was reduced following treatment and there was formation of healthy granulation tissue. Wounds were completely closed by skin grafting in three of these four cases and healed spontaneously in one case. One of the cases is presented in detail here.

**T**he global incidence of chronic wounds has increased in recent years, driven by the increase in aging and bed-bound populations, with a concomitant upsurge in peripheral arterial disease and diabetes. The lack of adequate tissue oxygenation stemming from poor blood circulation is a common characteristic of diabetic and pressure ulcers. Oxygen plays an important role in the wound healing process<sup>[1,2]</sup>, as well as in infection control<sup>[3-5]</sup>. Enhanced wound healing and a reduced bacterial burden are thus expected to be advantageous outcomes following the direct local administration of oxygen to chronic ulcers of the skin<sup>[6-10]</sup>.

Local topical oxygen wound therapy is widely employed in North American and European countries, with good reported efficacy<sup>[7,11,12]</sup>. In late 2010 after Institutional Review Board (IRB) approval, our research group at the Saitama Medical University Hospital (Saitama, Japan) initiated the first clinical investigation of this therapy in Japan and introduced this treatment with two case reports<sup>[13,14]</sup>. These reports looked at the efficacy of topical oxygen wound therapy in inducing healthy granulation tissue, improvement of transcutaneous oxygen tension and successful wound closure in patients with diabetic foot wounds and pressure ulcers. The following case report follows up on the initial study with results from six patients who presented at the hospital with either chronic diabetic leg or foot ulcers, or sacral pressure ulcers, providing full details of one case.

### Treatment protocol

Six patients with diabetic leg or foot ulcers ( $n=5$ ) or sacral pressure ulcers ( $n=1$ ) that had not healed in 3 months, despite use of best practice standard wound care — including surgical debridement and negative pressure wound therapy followed by moist wound dressings — were enrolled in the trial [Table 1]. In addition to IRB approval from the Saitama Medical University Hospital, informed consent was obtained from each enrollee. Local topical wound oxygen therapy was applied along with best practice standard wound care. Sharp debridement was performed in five cases ( $n=4$  diabetic ulcers;  $n=1$  sacral pressure ulcer) to remove unproductive and infected tissue. The single-use HyperBox topical wound oxygen (two2™) extremity chamber (AOTI, Oceanside, CA, USA) [Figure 1a] was employed for diabetic foot and leg ulcers, and the sacral topical hyperbaric oxygen chamber unit (AOTI) [Figure 1b] was employed for sacral pressure ulcers. Treatment was provided for 5 days a week, 90 minutes a day, according to the protocol recommended by the manufacturer. This treatment plan was continued for 4 weeks at the outset, or until spontaneous wound closure or sufficient granulation tissue formation was attained for operative wound closure via skin grafting.

The wound dressings were removed at the beginning of each treatment session. In the case of diabetic foot and leg ulcers, the affected

**Hitomi Sano** is Plastic Surgeon, University of Tokyo, Japan and Visiting Researcher, Saitama Medical University Hospital, Japan;  
**Shigeru Ichioka** is Professor of Plastic Surgery, Saitama Medical University Hospital

Figure 1. Topical wound oxygen therapy devices. a: Diabetic leg and foot ulcer extremity chamber device; and b. Sacral pressure ulcer unit device.

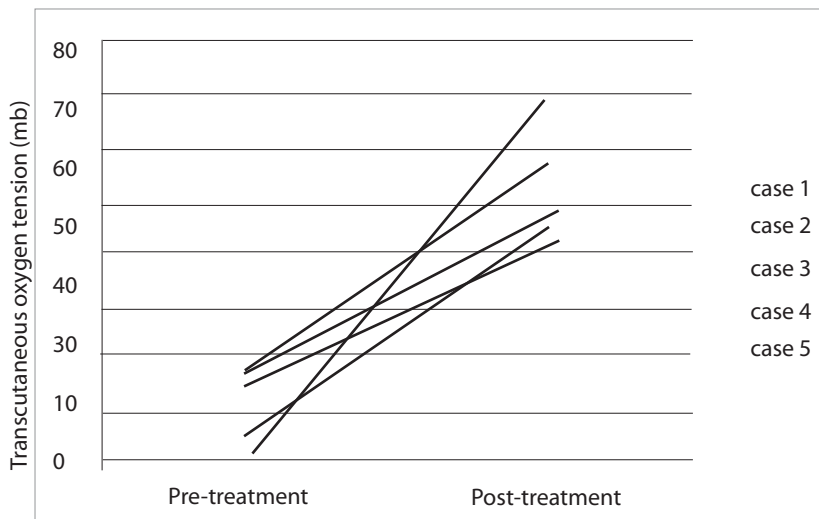
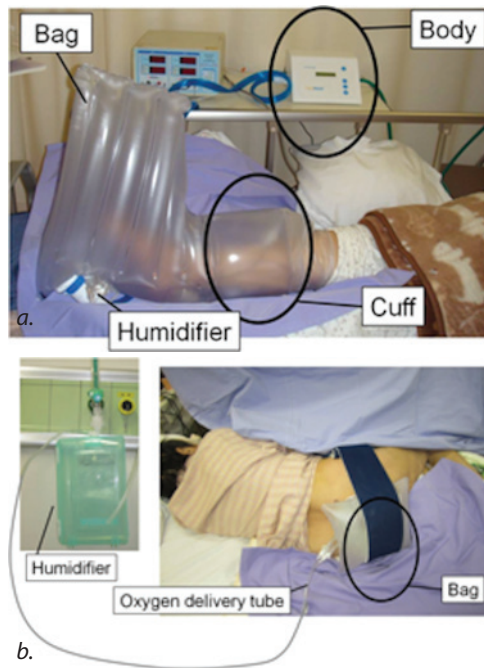


Figure 2. Oxygen tension before and after topical wound oxygen therapy. Pre- and post-treatment TcPO<sub>2</sub> values surrounding the ulcers showed an increase in oxygen tension at 1 day after the initiation of therapy.

Table 1. Patient data

Case number	Age	Sex	Wound site and size (including debrided area)	Complications
1	63	F	30 × 30 mm <sup>2</sup> : Right plantar	DM, HT, HL
2	70	F	100 × 40 mm <sup>2</sup> : Left toe necrosis	DM, PAD, CRF
3	55	M	40 × 30 mm <sup>2</sup> : Left 2nd and 3rd digit necrosis	DM, PAD
4	85	M	15 × 10 mm <sup>2</sup> : Left 5th digit necrosis and myelitis	DM, PAD
5	60	M	110 × 45 mm <sup>2</sup> : Right toe necrosis and myelitis	DM, PAD, CRF
6	80	F	100 × 120 mm <sup>2</sup> : Sacral pressure ulcer	DM, CRF

CRF: chronic renal failure, DM: diabetes mellitus, HT: hypertension, HL: hyperlipidemia, PAD: peripheral arterial disease.

limb was placed into the inflated single-use extremity chamber. The integral cuff was then inflated to seal the limb within the chamber. On commencement of the treatment, the device delivered 100% oxygen into the chamber. The pressure then intermittently increased and decreased between 5 and 50 millibars (mb) [Figure 1a]. To prevent the wound from drying out during the treatment, humidification was provided by means of an ultrasonic humidifier. In the case of the sacral pressure ulcer, the hyperbaric oxygen chamber unit was placed over the wound site using an adhesive ring, with a bag placed over the oxygen delivery tube and a foam band placed around the torso to hold the unit in place [Figure 1b]. The oxygen supply tubing was then connected to an oxygen source, and the pressure in the unit was regulated to remain at 30 mb.

Generally, pressure ulcers are associated with bacterial infection or critical colonisation, which creates an extensive amount of exudate. Hence, these wounds do not normally require humidification to prevent drying. However, if required, humidification can be provided via a simple bubble jet device, as shown in Figure 1b. Consensus statements from an expert panel suggest that TcPO<sub>2</sub> > 40 mmHg is usually associated with subsequent healing<sup>[15]</sup>. Transcutaneous oxygen tension (TcPO<sub>2</sub>) values surrounding the diabetic leg and foot ulcers and the sacral pressure ulcer were measured before and after treatment using a transcutaneous TCM400 oxygen monitor, as instructed by the manufacturer (Radiometer Medical, Copenhagen, Denmark). Wound recurrence and infection occurrence were assessed throughout the treatment period.

## Outcomes

Six cases were examined in this evaluation. No complications were experienced by any of the six patients during topical wound oxygen therapy. The post-treatment TcPO<sub>2</sub> in the vicinity of the ulcers were elevated at 1 day after treatment from the insufficient values (below 40 mmHg) to the adequate levels (above 40 mmHg) for wound healing in all six cases [Figure 2].

In four cases, robust tissue granulation was observed, and the wounds either healed spontaneously (*n*=1 diabetic ulcer) or were closed via skin grafting (*n*=2 diabetic ulcers; *n*=1 sacral pressure ulcer). One of these four cases (Case 3) is described in more detail below as a typical and successful case. Two additional diabetic ulcer cases (Case 4 and Case

5) showed no clinical improvement following topical wound oxygen therapy [Table 2]. In Case 4, the outcome was unknown because the patient voluntarily discharged himself after receiving debridement and 2 weeks of topical wound oxygen therapy, before completing the recommended 4-week treatment protocol. In Case 5, amputation of the affected lower limb was ultimately required as a result of severe local infection that could not be controlled.

### Case 3

A 55-year-old man presented with a diabetic foot ulcer affecting the second and third digits. The ulcer is shown after surgical debridement [Figure 3a]. The TcPO<sub>2</sub> value around the ulcer was very low, at 18 mmHg. Likely progression of necrosis was expected. However, a considerable amount of granulation tissue was formed at 4 weeks after the initiation of topical wound oxygen therapy [Figure 3b]. The wound healed spontaneously, and postoperative follow up indicated no ulcer recurrence in the following 2 months [Table 2].

### Discussion

Numerous publications support the promotion of fibroblast and vascular endothelial cell proliferation, as well as collagen synthesis, by exogenous oxygen<sup>[1,2]</sup>. Oxygen also plays a major role in infection control<sup>[4]</sup> by providing a direct

microbial growth inhibitory effect<sup>[3]</sup>, and also by activating neutrophils<sup>[5]</sup>. Therefore, therapeutic strategies that improve the availability of oxygen to injured tissues are of great interest in the field of wound repair.

Japanese insurance only covers full body systemic hyperbaric oxygen therapy for chronic wounds, and there are many reports ascertaining the usefulness of this modality in wound healing. However, this therapy can only be performed in major hospitals, because the implementation of large-scale devices is required, in addition to the need for highly trained medical personnel with qualifications accredited by the Japanese Society of Hyperbaric and Undersea Medicine<sup>[16]</sup>. Furthermore, many contraindications are associated with the use of systemic hyperbaric oxygen therapy, which limits patient suitability, as do potential systemic complications, including neurotoxicity and alveolar damage<sup>[17,18]</sup>.

In North America and Europe, alternative therapies are available that circumvent the risks and complications of systemic hyperbaric oxygen therapy by instead locally administering oxygen at the wound site. Topical wound oxygen therapy allows direct oxygen uptake by the injured tissue via an external delivery route, in contrast to full body systemic hyperbaric oxygen therapy, which relies on internal delivery via the vascular system. Moreover, topical wound oxygen systems are inexpensive and quite simple to use without the need for trained specialists. Topical wound oxygen therapy also does not pose the systemic risks seen with full body hyperbaric oxygen systems. Fischer first reported the usefulness of the new therapy in healing damaged tissue in 1969, even though the mechanisms of local oxygen therapy were unclear at that time<sup>[6]</sup>. Since then, elucidation of the advantages of direct oxygen uptake by the wounded tissue, and the development of topical wound oxygen devices, has resulted in enhanced interest and global use of this treatment.

Blackman et al<sup>[7]</sup> published a prospective controlled study in 2010 that explored the efficacy of topical oxygen therapy as an adjunctive modality in repairing diabetic ulcers that failed to heal by best practice standard wound care. All patients in the study received surgical debridement, offloading of the injured extremity, infection control, and selection of an appropriate dressing. The patients in the control group received silver-containing dressings, whereas the patients in the experimental group received simple dressings and local application

Table 2. Patient outcomes			
Case No.	Ischaemia	Revascularisation	Clinical outcomes
1	No	No	Healed by skin graft, no recurrence during 12 months
2	Yes	No	Healed by skin graft, no recurrence during 4 months
3	Yes	No	Healed spontaneously, no recurrence during 2 months
4	Yes	Yes	Self-discharged
5	Yes	Yes	Lower limb amputation
6	No	No	Healed by skin graft, no recurrence during 8 months

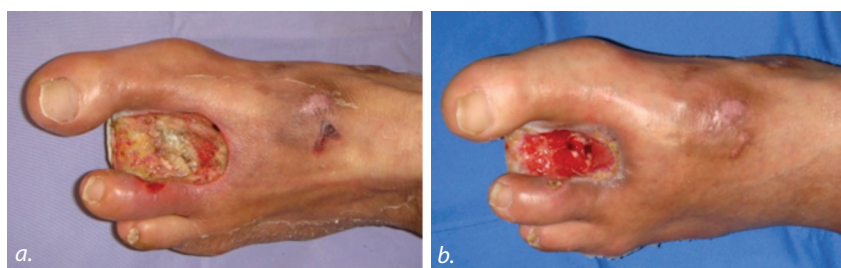

Figure 3. Diabetic foot ulcer; a. The debrided wound is shown prior to commencing topical wound oxygen therapy. b. The wound showed formation of healthy granulation tissue at 4 weeks after the commencement of oxygen therapy.

of oxygen for 60 minutes, 5 days a week. The complete healing rate after 12 weeks of topical wound oxygen therapy was an impressive 82.4% in the experimental group versus only 45.5% in the control group. Furthermore, the mean time to complete healing was significantly reduced in the experimental group compared with the control group (56 versus 93 days). The patients in the treatment group showed very low recurrence rates after 18 months, which was likely related to the augmented patency of the interlaced collagen fibers produced in the high-oxygen environment<sup>[7]</sup>.

Tawfick and Sultan<sup>[8]</sup> also investigated topical wound oxygen therapy in a prospective controlled study involving 83 patients with refractory venous ulcers. Both the control and the experimental group received best practice standard wound care from a team of vascular surgeons at a university hospital. Wound care included compression therapy in the control group, and daily local oxygen therapy in the experimental group. After 12 weeks of treatment, 80% of the ulcers were completely healed in the oxygen therapy group, as opposed to 35% in the compression therapy group. Similar to the Blackman et al<sup>[7]</sup> study, the mean time to complete healing was significantly reduced in the experimental group relative to the control group (45 versus 182 days). The patients were followed up for 36 months. The 2013 follow-up report demonstrated recurrence in 14 of the 30 healed ulcers in the compression therapy group, compared with only three of the 51 in the oxygen therapy group<sup>[19]</sup>.

The purpose of the current study was two-fold:

- To investigate the effect of topical oxygen therapy during the early stages of wound healing (as assessed by the formation of healthy granulation tissue, or immediately after surgical debridement but before skin grafting)
- To investigate the effect of this therapy on infection control.

TcPO<sub>2</sub> values were measured around the ulcer before and after topical wound oxygen therapy and, in all cases, the TcPO<sub>2</sub> was elevated after treatment. Four of the six patients presented with considerable formation of healthy granulation tissue and a decreased wound area. In the two patients in whom a significant therapeutic effect was not obtained (Cases 4 and 5), the TcPO<sub>2</sub> values before treatment were extremely low (<10mmHg). Hence, topical wound oxygen therapy may not be wholly curative in extremely severe ulceration cases. Additional studies with a larger number of patients are essential to validate long-term results, and to establish adaptation criteria.

## Conclusions

These case reports showed that local administration of topical oxygen to chronic diabetic foot and leg ulcers and to a sacral pressure ulcer effectively increased the TcPO<sub>2</sub> values in the periwound area. Topical wound oxygen therapy required no special skills, lending itself to ready application under most circumstances, even at a home site. The treatment has an extremely low risk of systemic complications, and single-use devices greatly reduce the possibility of secondary infections. Therefore, this adjunctive treatment modality is considered a useful means of treating chronic ulcers together with best practice standard wound care. Following this clinical study the authors are now trying to carry forward the procedures to obtain the approval of the device from the Pharmaceuticals and Medical Devices Agency of Japan, as well as resultant reimbursement by the Japanese national insurance system. WINT

**Conflict of interest:** *The topical wound oxygen therapy devices used in the study were provided by AOTI, Oceanside, CA, USA. The authors have no commercial, proprietary, or financial interest in the devices or the manufacturing company.*

## References

1. Rodriguez PG, Felix FN, Woodley DT, Shim EK. The role of oxygen in wound healing: a review of the literature. *Dermatol Surg* 2008; 34(9): 1159–69
2. Schreml S, Szeimies RM, Prantl L, Karrer S, Landthaler M, Babilas P. Oxygen in acute and chronic wound healing. *Br J Dermatol* 2010; 163(2): 257–68
3. McAllister TA, Stark JM, Norman JN, Ross RM. Inhibitory effects of hyperbaric oxygen on bacteria and fungi. *Lancet*. 1963; 2(7316): 1040–2
4. Asano S. Leukocyte. In: Uchiyama T, eds. *Miwa Hematology* 3rd edn, 292–5, Hakuohdo, Tokyo, 2006.
5. Hohn DC. Host resistance of infection. In: Hunt TK, ed. *Wound healing and wound infection*. 264–80, Appleton-Century Crofts, New York, 1980
6. Fischer BH. Topical hyperbaric oxygen treatment of pressure sores and skin ulcers. *Lancet* 1969; 2(7617): 405–9
7. Blackman E, Moore C, Hyatt J, Railton R, Frye C. Topical wound oxygen therapy in the treatment of severe diabetic foot ulcers: a prospective controlled study. *Ostomy Wound Manage* 2010; 56(6): 24–31
8. Tawfick W, Sultan S. Does topical wound oxygen (TWO2) offer an improved outcome over conventional compression dressings (CCD) in the management of refractory venous ulcers (RVU)? A parallel observational comparative study. *Eur J Vasc Endovasc Surg* 2009; 38(1): 125–32
9. Heng MC, Harker J, Csathy G, Marshall C, Brazier J, Sumampong S, Paterno Gomez E. Angiogenesis in necrotic ulcers treated with hyperbaric oxygen. *Ostomy Wound Manage* 2000; 46(9):18–28, 30–2
10. Leslie CA, Sapico FL, Ginunas VJ, Adkins RH. Randomized controlled trial of topical hyperbaric oxygen for treatment of diabetic foot ulcers. *Diabetes Care* 1988; 11(2): 111–5
11. Cronje FJ. Oxygen therapy and wound healing--topical oxygen is not hyperbaric oxygen therapy. *S Afr Med J* 2005; 95(11): 840

12. Tracey AK, Alcott CJ, Schleining JA et al. The effects of topical oxygen therapy on equine distal limb dermal wound healing. *Can Vet J* 2014; 55(12):1146–52
13. Sano H, Ichioka S, Tajima S, Sato T. Topical oxygen therapy for diabetic foot ulcer. *J Jpn P.R.S.* 2012; 32(1): 30–43 (Japanese)
14. Sano H, Ichioka S, Tajima S. Topical oxygen therapy for sacral pressure ulcer. *Japanese Journal of Pressure Ulcer.* 2012; 14(4): 605–9 (Japanese)
15. Fife CE, Smart DR, Sheffield PJ, Hopf HW, Hawkins G, Clarke D. Transcutaneous oximetry in clinical practice: consensus statements from an expert panel based on evidence. *Undersea Hyperb Med* 2009; 36(1): 43–53
16. Kawashima M, Tamura H, Noro S. Hyperbaric oxygen therapy. *MB Orthop* 1995; 8(3): 67–78
17. Hampson N, Atik D. Central nervous system oxygen toxicity during routine hyperbaric oxygen therapy. *Undersea Hyperb Med* 2003; 30(2): 147–53
18. Speit G, Dennog C, Radermacher P, Rothfuss A. Genotoxicity of hyperbaric oxygen. *Mutat Res* 2002; 512(2–3): 111–9
19. Tawfick WA, Sultan S. Technical and clinical outcome of topical wound oxygen in comparison to conventional compression dressings in the management of refractory nonhealing venous ulcers. *Vasc Endovascular Surg* 2013; 47(1): 30–7

## Expert commentary: role of oxygen role in wound healing

American Indians have believed for centuries that their wounds would heal quicker if they hiked down into the ‘richer’ air of the valleys<sup>[1]</sup>. Modern hyperbaric wound therapy began in the 1960s, when famous oceanographer Jacques-Yves Cousteau built a village under the Mediterranean sea. In 1962, Conshelf<sup>[1]</sup> was set up off the coast of Marseille, France at a depth of ten metres. Cousteau and his team noticed that small scratches and wounds seemed to heal faster in the humid and oxygen-rich environment of the underwater houses. This discovery led to the development and proliferation of modern hyperbaric chambers and hyperbaric medicine.

Treating patients in hyperbaric chambers is costly and is associated with a number of risks. With that in mind, American neurosurgeon Boguslav H. Fischer began using a miniature version of a hyperbaric chamber that provided oxygen topically onto the wound<sup>[2]</sup>. First results were published in 1966 and three years later. *The Lancet* printed a report on 56 patients treated successfully with topical wound oxygen<sup>[3]</sup>.

Oxygen is one of the major prerequisites for life. In mammals, all processes at the cellular level require oxygen, which is chiefly provided via the adenosine triphosphate (ATP) pump. ATP cannot be stored and its synthesis requires oxygen and glucose. Interestingly the molecular mechanism and the ATP pump were only clarified in the 1980s. The scientist Paul

D. Boyer und John E. Walker received the Nobel Prize in 1997 for their elucidation of the enzymatic mechanism underlying the synthesis of ATP. Most human organs receive required oxygen via the blood circulation and the lungs. However, the largest human organ — the skin — is partly supplied with oxygen by diffusion directly with the atmosphere<sup>[4]</sup>. The border between external and internal supply seems to be the stratum corneum of the skin.

In all phases of wound healing oxygen is also needed as a substrate for essential enzymatic processes. In the first (inflammatory) phase, neutrophils and macrophages build reactive oxygen species (ROS) which are important in fighting infection. When infected, the NADPH-linked oxidase ((nicotinamide adenine dinucleotide phosphate-oxidase, a membrane-bound enzyme complex) can increase oxygen consumption by as much as 50-fold. Up to 98% of the oxygen consumption of neutrophils is needed for ROS production. Newer research indicates that free oxygen radicals are important for cell signaling to stimulate cell migration, cell proliferation and neovascularisation<sup>[5,6]</sup>.

Oxygen delivery is a critical element in the healing of wounds. The pathophysiology of lack of oxygen in wounds is proven with a high evidence level. However, there is a lower level of clinical evidence, which may lead to a lack of topical oxygen use in wound care. Further clinical research in this area is

therefore needed, so this case study by Hitomi and Shigeru is welcomed. WINT

### References

1. Hunt TK, Pai MP. The effect of varying ambient oxygen tensions on wound metabolism and collagen synthesis. *Surg Gynecol Obstet* 1972; 135(4): 561–7
2. Fischer BH. Low Pressure Hyperbaric Oxygen Treatment of Decubiti and Skin Ulcers. *Proce Annu Clin Spin Cord Inj Conf* 1966; 15: 97–101
3. Fischer BH. Topical hyperbaric oxygen treatment of pressure sores and skin ulcers. *Lancet* 1969; 23, 2(7617): 405–409
4. Stücker M, Struk A, Altmeyer P, Herde M, Baumgärtl H, Lübbbers DW. The cutaneous uptake of atmospheric oxygen contributes significantly to the oxygen supply of human dermis and epidermis. *J Physiol* 2002; 538(3): 985–94
5. Dauwe PB1, Pulikkottil BJ, Lavery L, Stuzin JM, Rohrich RJ. Does hyperbaric oxygen therapy work in facilitating acute wound healing: a systematic review. *Plast Reconstr Surg* 2014;133(2):208e–15e
6. Löndahl M. Hyperbaric oxygen therapy as adjunctive treatment of diabetic foot ulcers. *Med Clin North Am* 2013; 97(5): 957–80



**Author:** Tom Wild, General Surgeon; Wound Center Dessau-Rosslau, Department of Dermatology, Dessau Municipal Hospital Dessau, Germany